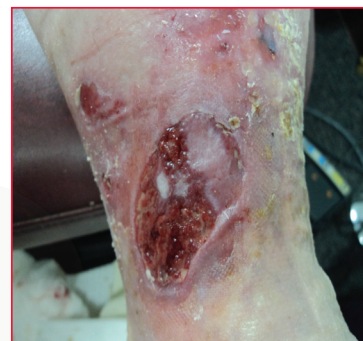

Sex	Female
Co-morbidities	<ul style="list-style-type: none"> • Non-insulin dependent diabetes mellitus • Congestive heart failure • Congestive obstructive pulmonary disease • Peripheral vascular disease
Wound Type	Mixed vascular
Wound Location	Left ankle
Wound Age	1 year
Previous Treatments	<ul style="list-style-type: none"> • Compression • Sharp debridement • Silver dressing • Steroid therapy
Secondary Dressing	<ul style="list-style-type: none"> • Non-adherent dressing • Rolled gauze • Compression therapy applicable to individual patient • Offloading pressure device
Outcomes	<ul style="list-style-type: none"> • Granulation tissue at Week 5 • Complete healing at Week 11

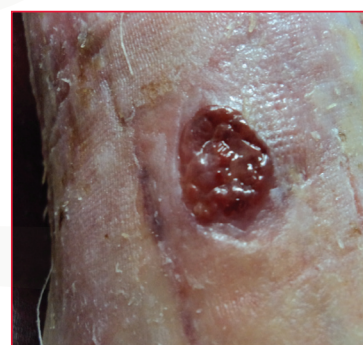
Endoform dermal template
Applications

9

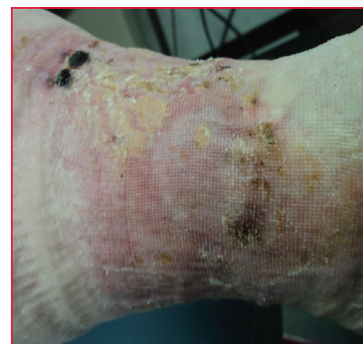0 Weeks



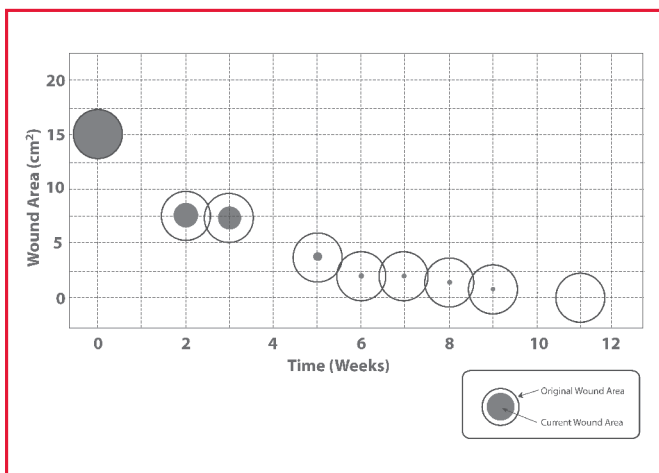
7 Weeks



11 Weeks



Wound area over time



CASE OVERVIEW

Initial Preparation

The wound was surgically debrided down to viable tissue and irrigated with hypochlorous acid solution and treated with a silver dressing and compression. The wound was assessed for visible signs of infection (i.e., absence of swelling, pain, purulent drainage, or tracking into the deep tissue planes). The wound had to remain free of infection to start using the Endoform dermal template. Silver dressing treatments were stopped at this time.

Endoform dermal template Application

Using aseptic technique, Endoform dermal template was trimmed to roughly overlap the wound margins, placed on the wound bed and rehydrated with sterile saline. Following hydration, the color of the dressing changed from white to opaque. Light pressure was applied to the dressing to ensure that it conformed to the underlying wound bed. The dressing was covered with a non-adherent secondary dressing. Compression stockings, exudate control and offloading were used as required.

Follow-Up

The patient received weekly follow-up, during which time the wound was debrided as required and irrigated to remove loose material. The Endoform dermal template was reapplied on a weekly basis. Changes in the wound granulation tissue, epithelial tissue and wound dimensions were monitored and recorded using digital photography.

Observations

In approximately three days, the dressing had adhered to the underlying wound bed. After seven days, the dressing was completely integrated into the wound bed. In some cases, only remnants of the dressing remained as an off-white gel that was allowed to remain in place during subsequent applications of Endoform dermal template.



Manufactured for
Hollister Wound Care
2000 Hollister Drive
Libertyville, IL 60048
1.888.740.8999

Distributed in Canada by
Hollister Limited
95 Mary Street
Aurora, Ontario L4G 1G3
1.800.263.7400

www.hollisterwoundcare.com

Reference:
Liden BA, Ward BR, May BCH; Early Clinical Findings From The Use Of Endoform Dermal Template (Ovine Forestomach Matrix) To Treat Recalcitrant Wounds; Presented at Symposium on Advanced Wound Care, April 14-17, 2011 Dallas, TX.

CAUTION: Federal (USA) law restricts this device to sale by or on the order of a physician.
Prior to use, be sure to read the entire Instructions for Use package insert supplied with the product.
922208-0213

Hollister and Logo is a trademark of Hollister Incorporated.
Endoform is a trademark of Mesynthes Limited.
©2013 Hollister Incorporated.